

Newsletter 05 / 2016



We are pleased to welcome you to the monthly BattLab newsletter. This newsletter will bring you the latest news and information about our laboratory and all tests that we can offer to all our clients.

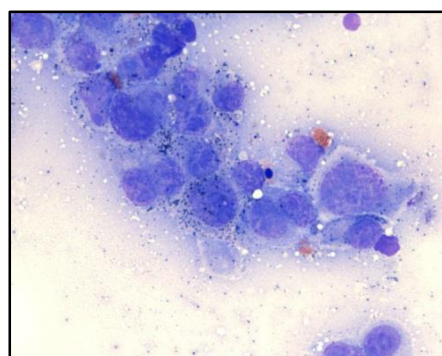
Escherichia Coli can be a friend or an enemy...

Escherichia coli are normally friendly bacteria that form part of the complex microflora in the gastrointestinal tract enjoying a symbiotic relationship with the host. However, certain *E. coli* can cause gastrointestinal disease. Molecular detection of pathogenicity genes by PCR has revealed enteropathic strains in dogs and cats which are indistinguishable from harmless *E. coli* by normal faecal culture. These enteropathic forms of *E. coli* (enteropathogenic – EPEC, verotoxigenic – VTEC, enterohaemorrhagic – EHEC, enterotoxigenic – ETEC, enteroaggregative - EAggEC) may all cause acute gastrointestinal disease, but properties such as adherence to the mucosal surface by EPEC can also predispose to chronic disease. Veterinary surgeons can request either the acute or chronic ***E. coli* PCR** panel by sending faecal samples to our laboratory. **Autologous *E.coli* vaccines** can also be made upon request. For more information, don't hesitate [to contact us](#).

Cytology picture of the month

This picture is from an aspirate from an enlarged popliteal lymph node of a dog with a cutaneous mass on the leg (Wright Giemsa, 100x). What is your diagnosis?

The submitted sample has adequate cellularity and preservation. There is a lightly basophilic background with small numbers of dark granules. Interestingly, there are no lymphoid cells, but a population of pleomorphic cellular elements. These have moderate amount of basophilic cytoplasm, occasionally slightly elongated, with poorly defined borders, frequently containing small



numbers of dark granules, likely melanin. These cells show significant cytological features of atypia, mostly anisocytosis (variation in cell size), anisokaryosis (variation in nuclear size) and binucleation. Cells also show prominent round nucleoli.

These cytological features are indicative of melanoma, likely metastatic since this is an aspirate from a lymph node. The absence of lymphoid cells is likely due to an advanced metastatic disease, where the lymphoid cells component has been completely effaced by the neoplastic population.

A previous study (Williams LE, J Am Vet Med Assoc, 2003) showed that over 30% of dogs with proved cytological and histological evidence of lymph node metastases of melanoma had lymph nodes of normal size.

These data show that size alone is insufficient for accurate clinical staging of oral malignant melanoma in dogs, and cytologic or histologic examination of regional lymph nodes should routinely be performed, regardless of size of those nodes.

Our laboratory offers a comprehensive cytology service for all domestic species. This is provided by on-site board certified clinical pathologists with a turnaround time typically within 24 hours from the receipt of the sample. For more information, please contact the laboratory.

Next Seminar

We are pleased to announce the second of our **series of seminars** at BattLab, addressed to veterinarians and focused on pruritus.

Title: "Why does this dog itch?"

Date: Wednesday 28th of June 2016, Starting 19:30

Venue: The Venture Centre, University of Warwick Science Park, Sir William Lyons Road, Coventry CV4 7EZ



Spaces still available! Contact the laboratory (admin@battlab.com) for registration.

More seminars will follow soon. Keep an eye to our **Facebook page** for more information:

www.facebook.com/BattLab

60 seconds with...

We hear from Regina Wagner, Specialist in Veterinary Dermatology at Laboklin.

How long have you been at Laboklin?

Since 2004 I am a consultant for Laboklin, I did do lectures for Laboklin already before 2004

Why do you do what you do?

I love veterinary dermatology! I did it since the end of my studies of DVM already and I did never something else in my professional career.



What do you enjoy doing in your spare time?

Spare what? ☺ My main job is "Mama Taxi" for my children. But other than that I love to work on my farm, with my animals and being outside in nature.

Yours sincerely,

The BattLab team



Telephone: 024 7632 3275

Fax: 0871 750 5323

Email: admin@battlab.com

Website: www.battlab.com